The specific case

Surgical treatment of a olecranon fracture, partial non-union with **CERASORB® Foam**

Drs. E.J. Hekma
Rijnstate Hospital
Arnhem, NL

CERASORB®-PROMISE

CERASORB®.
Keeps its words in bone regeneration.

curasan
Regenerative Medicine

The specific case

Olecranon fracture, partial non-union

Surgical treatment of a olecranon fracture, partial non-union with **CERASORB® Foam**

„In this case, the use of the synthetic, fully resorbable pure-phase β - Tricalcium-phosphate ***CERASORB®*** *is an appropriate solution for the management of a partial non-union. Moreover, the foam version of* ***CERASORB®*** *has shown excellent intraoperative handling characteristics with an unparalleled ease-of-use."*

Drs. E.J. Hekma - Trauma Surgeon
Rijnstate Hospital
Arnhem, NL

[Fig. 1]

[Fig. 2]

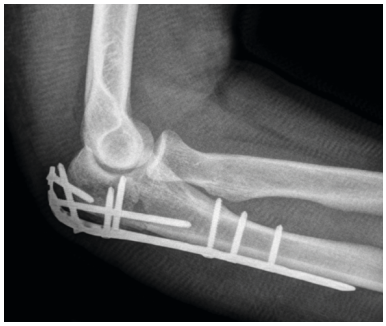

Anamnesis
A 57-year old male crashed with his bicycle resulting in a comminuted right olecranon fracture [Fig. 1]. Two superficial lesions could be observed on his elbow. He was operated on November 12, 2014 by using internal plate fixation via ORIF (Synthes® LCP Olecranon plate)

3

T = Months

In February 2015 the patient showed signs of an infected osteosynthesis. Osteolysis around one of the screws was suspected. The patient was treated with Augmentin®.

No signs of consolidation could be observed in the follow-up period [Fig. 3] and the patient was re-operated on June 26, 2015.

[Fig. 3]

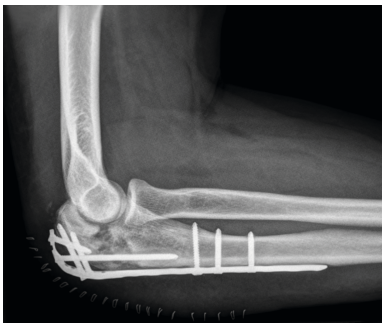

A new plate was implanted following debridement and the bony defect was grafted with autologous bone chips harvested from the tibial head [Fig. 4]. The treatment with Augmentin® was continued.

[Fig. 4]

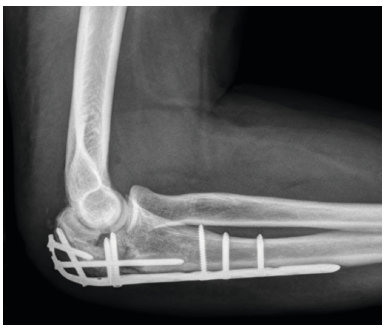

6

10

In October 2015, the patient underwent electrostimulation to stimulate bone healing, however, without any satisfying result.

Surgical treatment with CERASORB® Foam

On January 25, 2016 the patient was operated for the third time. X-ray and CT scans had revealed a relatively large partial non-union [Figs. 5 and 6]. There were no signs of infection.

[Fig. 5]

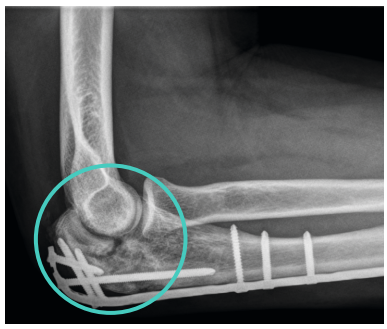

[Fig. 6]

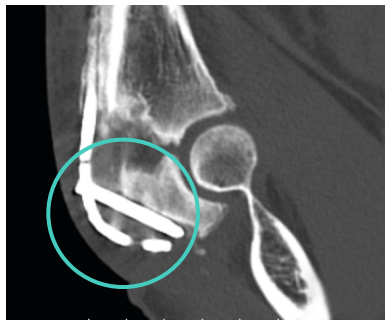

The plate was removed and the defect was debrided and filled with 10 cc of **CERASORB® Foam** (synthetic, fully resorbable, pure-phase β -TCP + porcine collagen matrix bone graft substitute) [Fig. 7].

The patient received a removable cast for 6 weeks. Directly post-op he started with isometric exercises.

[Fig. 7]

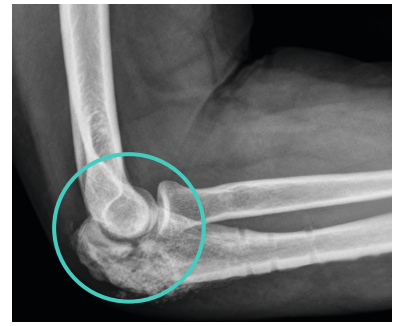

Follow-up and discharge
The x-ray of March 4, 2016 was indicative of an ongoing remodeling process, the bone graft substitute being gradually resorbed and replaced by endogenous new bone [Fig. 8].

[Fig. 8]

On June 6, 2016, the x-ray showed a far progressed remodeling into new bone [Fig. 9].

Any **CERASORB® Foam** present in small amount in the soft tissues was resorbed, with no risk of ectopic bone formation. The patient had a full range of motion, no more complaints, was back to work and had restarted cycling.

[Fig. 9]

16

19

Case history and x-ray images by courtesy of: Drs. E.J. Hekma - Trauma Surgeon, Rijnstate Hospital, Arnhem, NL

Take home messages

- Grafting with **CERASORB® Foam** has shown to be an appropriate solution in this case.
- **CERASORB® Foam**, a fully resorbable, synthetic pure-phase ß-TCP-collagen bone graft substitute, can offer appropriate solutions for the management of partial non-unions.
- It can be discussed whether the addition of bone marrow aspirate or autologous bone graft material to the osteoconductive scaffold **CERASORB® Foam** may be necessary to manage these kinds of defects which are at higher risk of non-healing (partial non-union, specific drug usage, low grade infection in anamnesis).
  In this case, bone marrow aspirate was not added, still resulting in the desired outcome.

Maximum flexibility

CERASORB® Foam

CERASORB® Foam is a pure-phase, fully synthetic ß-TCP-collagen scaffold. the product is available in both, a mouldable and flexible foam version.

Type of use:

- As stand alone in critical-size metapyseal or segmental defects not requiring additional cells and growth factors.
- In combination with autologous materials in defects requiring additional cells and growth factors.
- In combination with autologous bone chips
- In combination with RIA
- In combination with bone marrow aspirate

Handling:

- **CERASORB® Foam** can be moulded when soaked with patients blood or bone marrow aspirate in a ratio of 1:1
- **CERASORB® Foam** can be cut in small pieces to facilitate combination with autologous materials.

CERASORB® bone-regeneration materials.
We offer tailor-made solutions for diverse requirements.

You have our word!

curasan
Regenerative Medicine

curasan AG
Lindigstrasse 4
63801 Kleinostheim
Germany
cerasorb@curasan.de
www.curasan.de

The specifications on the inserts enclosed with CERASORB® products are binding

1108600033_09_2016_001

CERASORB® – Always First Choice.